Orthopedic Terms to Know

Dorsal - upper or back

Palmar

Plantar

Volar - on palmer or plantar side (volar wrist is on palmer side of wrist)

Inversion - turning inward (sole of foot turns in) (ankle rolls out)

Eversion - turning outward (ankle goes in)

Abduction - move away from midline (spreading fingers/toes apart)

Adduction - move toward midline (bringing toes/fingers together)

Valgus - segment distal to a joint is turned outward/away from midline

Varus - segment distal to a joint is turned inward/toward midline

Pronation - Palm of hand down or ankle everted/turned in

Supination - Palm of hand up

External rotation - Rotate away from midline

Internal rotation - Rotate toward midline

Ulnar deviation - turned toward ulnar side of wrist

Radial deviation - turned toward radial side of wrist

Flexion - bent or moving in a forward/anterior direction

- For foot: dorsiflexion and plantarflexion
- For hand: dorsiflexion and palmar flexion
- For shoulder: elevation, upward motion of arm

Extension - straightening (increasing the angle) or moving in a posterior direction (neck, hip)

Contusion - bruise

Strain - affected muscle

Sprain - affected ligament

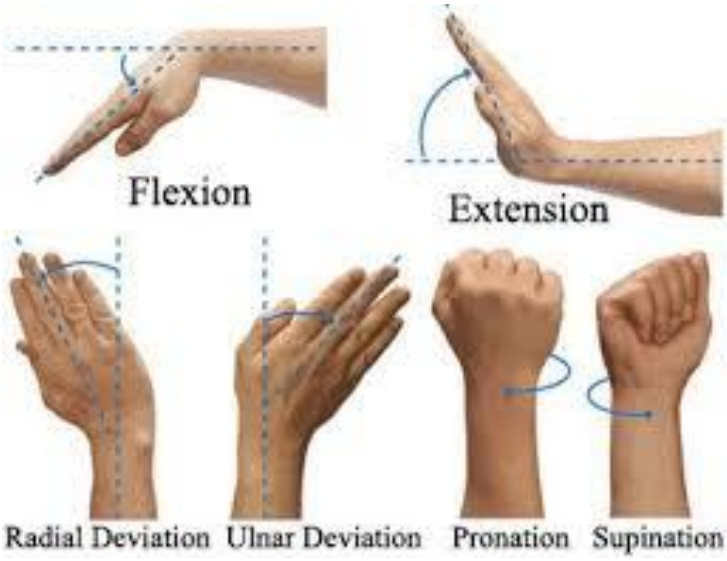

Orthopedic Assessment
A Pain in the Neck…or shoulder

Valerie Verbist, APNP
Department of Juvenile Corrections

TERMS OF ENDEARMENT

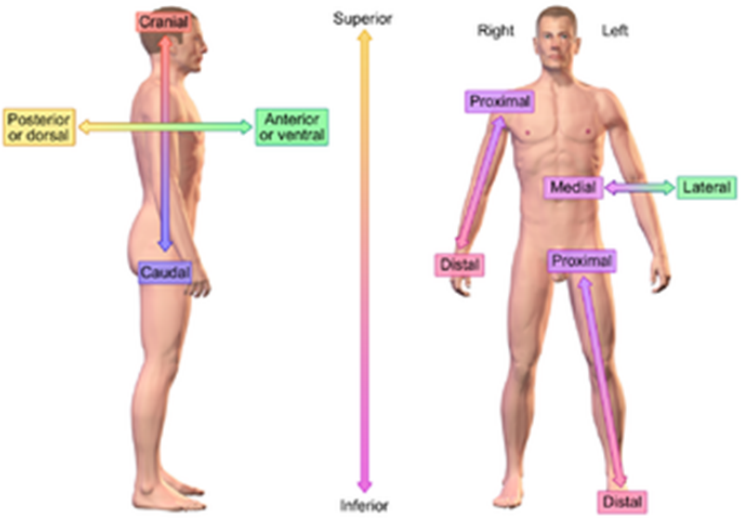

Directional References

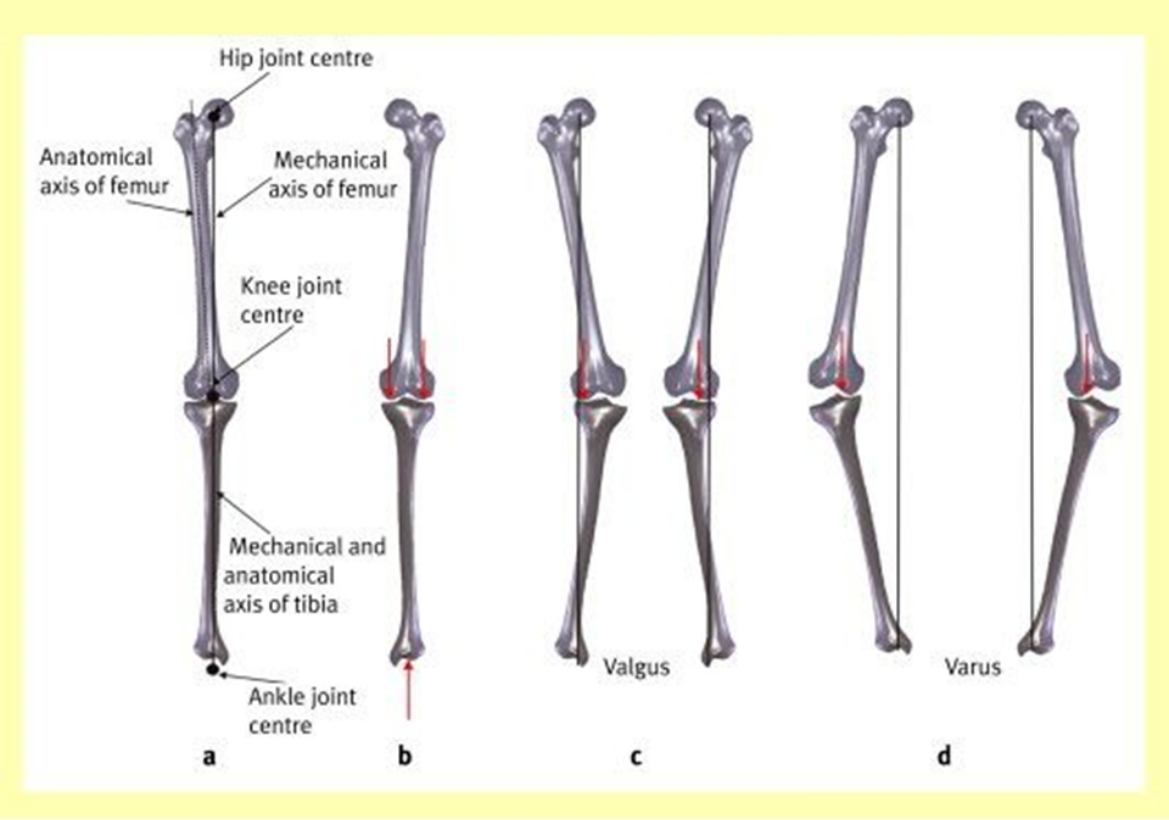

History/Subjective Data

- Location of discomfort
- Onset/duration of discomfort
- Description of pain (type of pain, progression)
- Previous injury to area
- Exacerbating/relieving factors
- Associated weakness or sensory abnormalities
- Functional abilities
- Constitutional symptoms
- If injury:
  - Could they keep participating
  - Mechanism of injury
  - Concomitant injury

Physical Examination

- Swelling
- Bruising
- Deformity
- Muscle tone/symmetry
- Neurovascular check (color, temp., cap. Refill, pulse, numbness)
  - If neurovascular compromise-have about 4 hours before severe tissue injury
- Range of motion at affected/nearby joints (should consider assessing joint above and below)
  - Be careful-if obvious fracture, do not have them move
- Skin assessment
  - Any open areas - consider possible open fracture

HAND INJURIES

- Assess each joint near affected area
- Assess for flexion and extension at joints
- Look for any obvious deformity
- Note skin integrity

EXTENSOR TENDON INJURY

- Fingers - if they can't straighten at a joint, consider extensor tendon injury (mallet finger)
  - Usually caused by direct blow to tip of finger
  - Can be from an avulsion fracture
- Treatment: Splint in extension (Stax splint) – Refer to provider

FLEXOR TENDON INJURY

- If they can't flex at a joint, consider flexor tendon injury (i.e. jersey finger)
  - Usually DIP joint affected
  - MOI: Usually hyperextension
- Treatment: splint in slight flexion (not extension).
  - Needs surgery

METACARPAL FRACTURES

- Usually result of direct force/trauma
- 5th metacarpal neck most common site (Boxer's fracture)
- Treatment: Splinting
  - Splint with wrist in 20 to 30 degrees of extension, the MCPs at 70 to 90 degrees of flexion, and the PIP and DIP in slight flexion
  - Can require surgical intervention

CARPAL FRACTURES

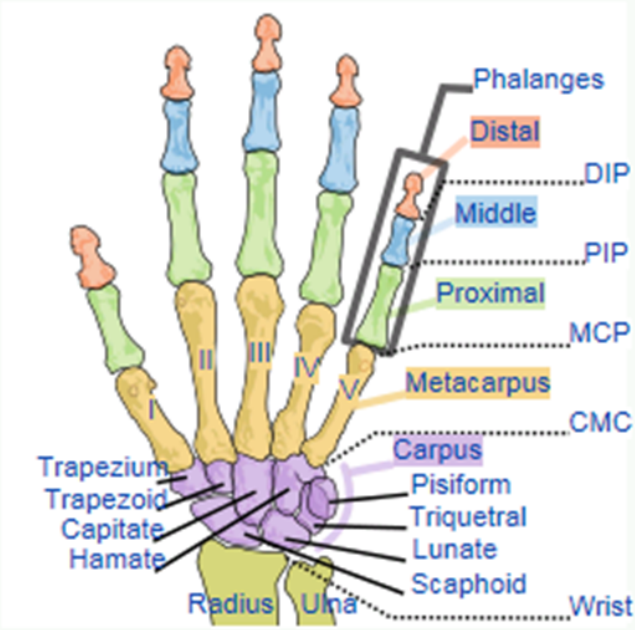

Carpal bones and their articulations. Carpal bones are shown in violet. Human left hand, anterior (palmar) view.

CARPAL FRACTURES

- Scaphoid is most commonly fractured
  - FOOSH is most common MOI
  - Assessment findings-
    - Anatomic snuffbox tenderness
    - Pain on radial side of wrist
    - Swelling on radial side of wrist
  - Risk of nonunion and AV necrosis if not properly treated
  - Triquetrum is 2nd most common carpal bone fractured
  - Treatment for both: Immobilize, Ice, Pain control

FOREARM FRACTURES

- Usual MOI: FOOSH
- Radial fracture
  - Forearm rotation limited

Elbow

- Epicondylitis
  - Medial (golfer's elbow)
  - Lateral (tennis elbow)
- Bursitis
- Bicep rupture

SHOULDER

- Dislocation - risk for neurovascular compromise

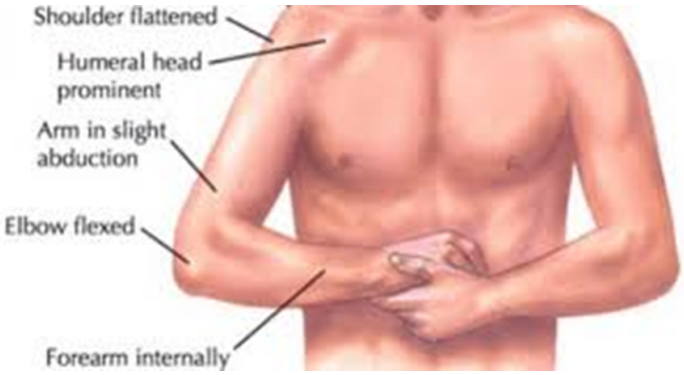

AC Separation

- Usually from fall on lateral shoulder
- Worse w/lifting arm

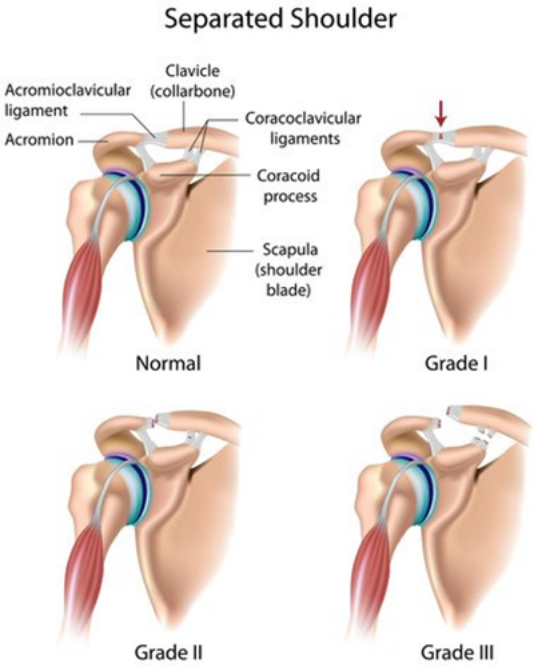

Clavicle Fracture

- Deformity can usually be seen or felt

More Shoulder

- Rotator cuff injury
- Adhesive capsulitis
- Consider possible cervical origin

Spine

- Assessment:
  - Palpate spinous processes
  - Flexion
  - Extension
  - Lateral bending
  - Rotation
  - Heel walking and toe walking
  - Straight leg test

Canadian C-spine rules (use w/trauma)
- Age >65 years
- Dangerous MOI
- Extremity parasthesias

Neck Pain

- Neck sprain
  - Follows injury, worse w/activity
- Cervical radiculopathy
  - Follows dermatomal pattern

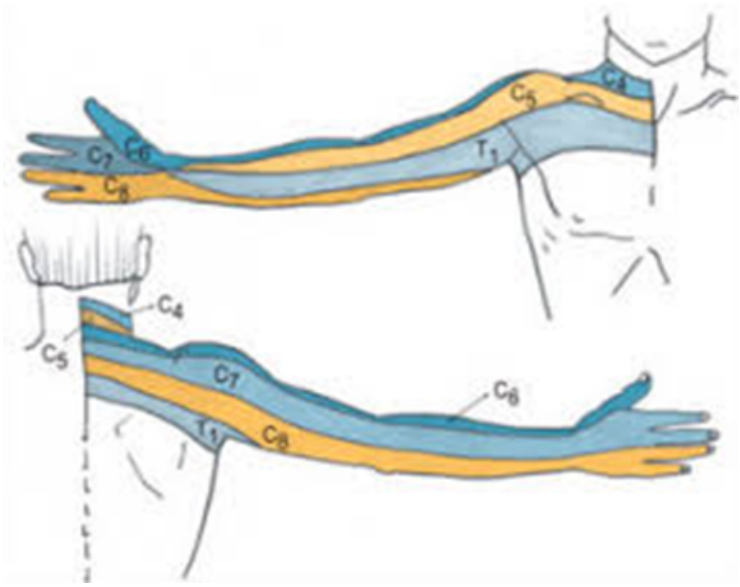

Back Pain

- Lumbar radiculopathy
- Low back pain
- Spinal stenosis
- DJD

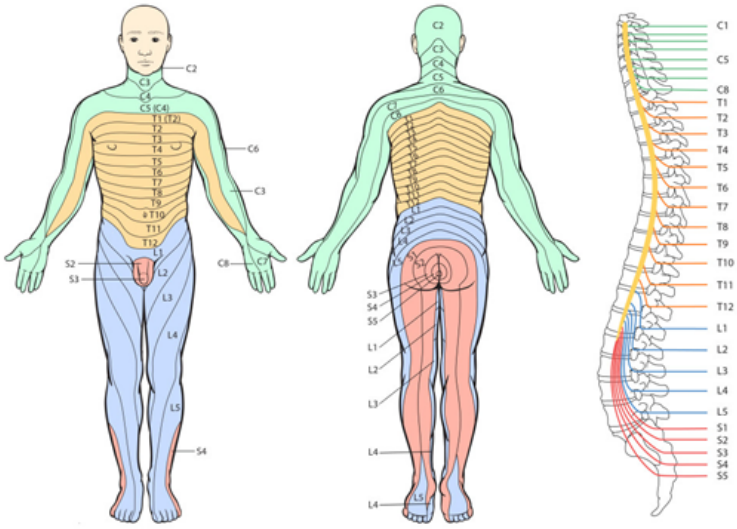

Back Pain

- Extraspinal causes of back pain:
  - Inflammatory bowel disease, retroperitoneal lesions, aortic aneurysms, reproductive tract cysts or tumors
- Red flags:
  - Fever or chills
  - Night sweats
  - Weight loss
  - Nocturnal pain
  - Loss of bowel/bladder control
  - Neurologic abnormalities

Hip

- Assessment:
  - Abduction and adduction
  - Internal and external rotation
  - Flexion
  - Observe gait

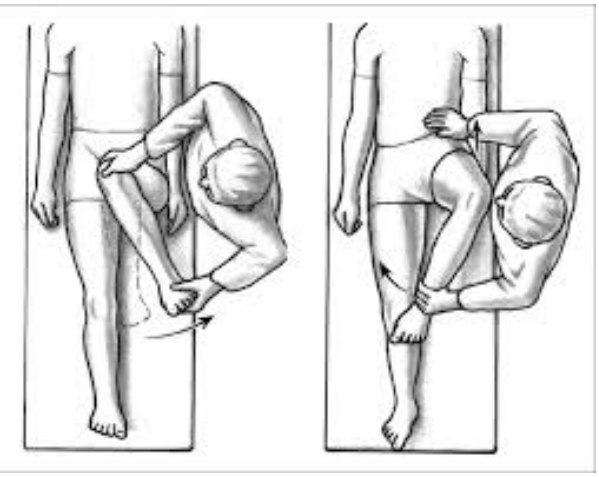

Hip

- Hip fracture
  - Pain in groin or buttock
  - Leg often shortened and externally rotated
- Trochanteric bursitis
- Osteoarthritis
  - Usually pain in thigh or groin
  - Decreased ROM (especially internal rotation)
- Consider referred pain from lumbar spine
- Nonmusculoskeletal pathologies:
  - Inguinal hernia, IBD, nephrolithiasis, diverticulitis, appendicitis, testicular torsion or neoplasm

Knee

* Assessment:
  * Ask about mechanical symptoms, stiffness and instability
  * Palpate knee (including joint lines)
  * Patella mobility
  * Valgus/varus strain
  * Anterior/posterior drawer test

* Ottawa knee rules – x-ray recommended if…
  * Acute injury in patient >55 y.o.
  * Isolated tenderness over patella
  * Tenderness at fibular head
  * Cannot flex knee to 90º
  * Unable to bear weight immediately after injury and 4 steps into clinic

Knee

* Meniscal injury
* ACL tear
* Arthritis
* Tendinitis
* Popliteal cyst

* Remember that claudication can mimic knee pain

ANKLE

- Ottawa ankle rules – x-ray if…
  - Unable to bear weight at time of injury and 4 steps into clinic
  - Pain over posterior edge or tip of medial or lateral malleolus
  - Pain over base of 5th metatarsal or navicular area

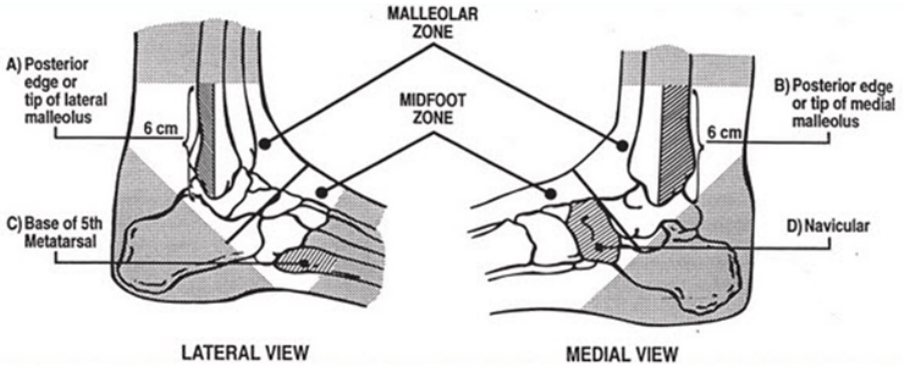

FOOT

- If bilateral pain, consider systemic or spinal etiology

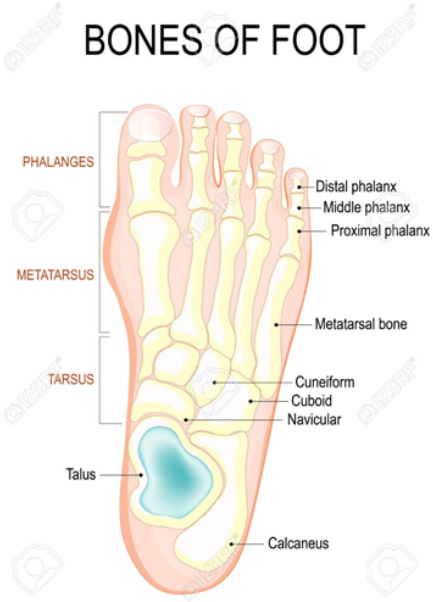

ORTHOPEDIC EMERGENCIES

- Possible infected joint
- Open fracture/unstable fracture
- Compartment syndrome or neurovascular compromise
- Cauda Equina